14

Studies on the Pituitary Gland of *Xiphophorus maculatus* (the Platyfish)[1]

MARTIN P. SCHREIBMAN

Biology Department, Brooklyn College of the City University of New York

(Plates I-V; Text-figure 1)

INTRODUCTION

IT is generally accepted that histological and cytological variations in the hypophysis reflect the physiological state of the individual. Although a large body of information relating pituitary gland structure to function in mammals is available, comparatively little is known about the pituitary gland in fishes under different physiological conditions. This may be attributed, in part, to the difficulty of handling and studying these tiny glands with their extremely small cells. General pituitary morphology and histology have been described in many fishes, but there is only a modicum of information dealing with detailed cytological analysis. The more refined staining methods that have been applied to mammals *(e.g.,* Halmi, 1950, 1952; Hildebrand, Rennels & Finerty, 1957; Purves & Griesbach, 1951 a, b, c) have been utilized in studies of fish pituitaries in only a few instances *(e.g.,* Atz, 1953; Barrington & Matty, 1955; Sokol, 1961; Van Mullem, 1958).

The platyfish *(Xiphophorus maculatus)* of the Genetics Laboratory of the New York Aquarium, New York Zoological Society, present a unique opportunity to analyze the relation between the endocrine system and normal and abnormal development. These valuable experimental animals of known genetic constitution can be obtained at any stage of their ontogeny with or without thyroid tumors, melanomas, castration and endocrine transplantation. Essential to any analysis of the functions of the platyfish pituitary is a comprehensive report on its normal histology and cytology. Some published information dealing with the histology and cytology of the platyfish hypophysis comes from investigations dealing mainly with other aspects of fish endocrinology, but because of inadequate techniques these are of limited value.

The objectives of the present investigation, therefore, are to present a comprehensive report on the morphology, histology and cytology of the pituitary gland in normal, sexually mature male and female platyfish. In addition, structural modifications in the pituitaries of platyfish under the following conditions will be presented and analyzed:

(a) Platyfish one to eight weeks of age.
(b) Aging female platyfish.
(c) Gravid female platyfish.
(d) Castrated male platyfish.
(e) Platyfish with thyroid tumors.
(f) Platyfish—swordtail hybrids with melanomas.

ACKNOWLEDGMENTS

I express my sincere appreciation to Dr. Harry A. Charipper of New York University for supporting this project and for providing an opportunity to complete this study; to Dr. Klaus D. Kallman of the Genetics Laboratory of the New York Zoological Society for suggesting this study and for his generosity in supplying the fish, including the gonadectomized specimens; to Dr. James W. Atz for critically reading the manuscript and making valuable criticisms in its preparation. I am especially indebted to Dr. Albert H. Stenger of New York University for his encouragement, guidance and helpful criticism in all phases of this investigation.

MATERIALS AND METHODS

The 118 platyfish used in this investigation were members of strains (Table I) maintained at the Genetics Laboratory of the New York Zoological Society, under conditions described

[1]From a dissertation submitted to the faculty of the Graduate School of Arts and Science in partial fulfillment of the requirements for the degree of Doctor of Philosophy at New York University.

TABLE I. PROFILE OF PLATYFISH AND HYBRIDS UTILIZED IN THIS INVESTIGATION

Category	Pedigree & Strain	Number Females	Number Males	Age Range (Months)
Sexually Mature	30, 163, C30	16	20	4-12
Immature	C30	13	13	1-8 (weeks)
Old	G981	8	0	28-33
Old Control	G1064, G1137	4	4	5-9
Gravid Female	163, M1, G1064	7	0	5-10
Castrate Male	30×163, C30	0	9	5-8
Heterotopic Thyroid Tumor	995, 996, 987, 163	6	3	12
Melanoma	M1, M2	4	4	5-12
Melanoma Control	M1	5	2	6-8

by Gordon (1950). The inbred strains 30 and 163 originated from specimens collected in the Rio Jamapa, Mexico, in 1939. Strain C30 is essentially identical in its genetic makeup with strain 30 except that one of its X chromosomes has been derived from a Rio Coatzacoalcos strain by introgressive hybridization. The Rio Grijalva strain (G) has been maintained in the laboratory since 1952. Pedigree numbers 995, 996 and 987 are hybrids of Coatzacoalcos platyfish mated to the 30 strain. Strain M1 was created by introducing a *maculatus* chromosome carrying the *Sd* gene into the 3B (Rio Papaloapan) strain of the swordtail, *Xiphophorus hellerii,* by introgressive hybridization. The M2 strain was maintained by mating *X. maculatus-X. hellerii* hybrids with each other.

To ascertain the morphological, histological and cytological status of pituitaries in mature male and female fish under non-experimental conditions, four- to twelve-month-old animals were sacrificed at various periods during a complete year. In order to include structural variations associated with aging, immature and aged platyfish were utilized. The immature group comprised individuals one, two, three, four, six and eight weeks postpartum. The sex of these juveniles was determined by sex-linked pigmentary patterns (only females carried the *Sd* gene for dorsal fin spotting). Aged fish were represented by 28- to 33-month-old individuals reared in the laboratory. Male fish castrated at one to four months of age and sacrificed four to seven months later formed the basis for study of the effect of orchidectomy. Fish were used only after gonadectomy had been confirmed by arrested gonopod development and by the absence of testicular tissue at autopsy. Normal mature males of the same age constituted the controls. When certain strains of *Xiphophorus maculatus* are subjected to an iodine-deficient environment by rearing them in distilled water, they develop heterotopic thyroid tumors (Baker, 1958 a, b; Baker, Berg, Gorbman, Nigrelli & Gordon, 1955; Mac Intyre, 1960). In the present investigation, pituitaries were taken only from animals with well-developed heterotopic thyroid tumors. Controls were siblings and mature animals of similar genetic constitution maintained in conditioned aquarium water. Melanotic tumors occur regularly in the hybrid offspring of matings between black-spotted platyfish and swordtails (Gordon, 1951). Only fish with well-defined pigmented tumors were considered, and comparisons were made with non-melanomatous fish from closely related pedigrees and with normal, mature platyfish and swordtails.

Mature specimens for study were taken from Genetics Laboratory aquaria and immediately decapitated just posterior to the operculum. The gill chamber was cleared of tissue and the pituitary exposed by removing the roof of the buccal cavity. The heads were placed in fixing fluid within 60 seconds of decapitation, and after fixation and washing they were partially dehydrated and hardened in 70% and 80% ethanol. The brain and attached hypophysis were then removed from the skull, extrinsic tissue trimmed down and the preparation subjected to final dehydration. Immature specimens (one to eight weeks old) were killed by severing the spinal cord at the base of the skull without separating the head from the body. The snout was trimmed off to the level of the eyes, an incision made into

the coelom and the bodies placed in fixing solution. Because extirpation of the pituitary was difficult, juvenile fish were decalcified, after fixation, in a 5% to 6% suspension of disodium ethylenediamine tetracetate (Sequestrene AA of the Alrose Chemical Co., Providence, R.I.) in 10% aqueous formalin. This method satisfactorily softened the bones and did not interfere with subsequent staining.

Consistent and dependable results were obtained from material fixed in Helly's fluid, formol-sublimate (1 part formalin and 9 parts saturated aqueous mercuric chloride) and Elftman's (1957) chrome alum solution. Fixing agents containing acetic acid did not generally produce suitable preparations. They brought about lysis of cells or clumping and shrinkage of cytoplasmic material. All fixatives were prepared immediately prior to use.

Dehydration of all material was accomplished by using the Zirkle normal butyl alcohol series, as described by Krajian (1940, p. 212). Infiltration and subsequent embedding was achieved with 56°-58° C. embedding paraffin. Complete penetration of paraffin into the cavity of immature fish was insured by infiltrating in a vacuum paraffin oven for thirty minutes at 50 to 150 mm. of mercury and sixty minutes at 62° C. at atmospheric pressure. In order to secure proper orientation for sectioning, brains and attached pituitaries and whole juvenile fish were embedded under a dissecting microscope and the cutting plane marked by a fine bristle.

Serial sections, four micra thick, were cut in transverse, frontal and sagittal planes and stained with the following techniques:

(1) The Heidenhain's azan method as adapted by Dawson & Friedgood (1938) with some minor changes, *e.g.*, less time in the orange G-anilin blue counterstain. This method produced excellent and consistent color differentiation of cell types.

(2) Masson's ponceau-acid fuchsin, anilin blue technique (Lillie, 1954, p. 351). A 1 percent. phosphotungstic acid was substituted for phosphomolybdic acid.

(3) The periodic acid-Schiff reaction for glycoprotein as described by Purves & Griesbach (1951a).

(4) The Halmi (1952) modified aldehyde fuchsin technique of Gomori (1950). Elftman's (1959) oxidation procedure was employed as a supplemental step.

Adjacent sections from each of the several representative pituitaries were stained by the above techniques and in this manner a comparative picture of the reaction of cells to a number of techniques was secured. Stained slides were cleared in xylene and mounted in clarite in xylene.

Differential cell counts were determined from four micra, sagittally serially sectioned glands at 1800 × magnification. For each specimen, three sections were utilized: one section from the mid-region and one section from each lateral half of the gland. All cells were classified and counted in a band 58 micra wide that extended from the anterior to the posterior margins of the gland and therefore included the pro-adenohypophysis, meso-adenohypophysis and meta-adenohypophysis. A blue filter (Eastman Kodak H filter #45) was utilized to accentuate the acidophils and a light green filter was employed to differentiate cyanophils from chromophobes.

All dimensions were determined with the aid of an ocular micrometer, and in non-spherical bodies represent the two longest perpendicular axes. Cell and nuclear values represent an average of the measurement for several cells. The terms "length," "width" and "depth," as applied to the total gland, require clarification. Length is the linear measurement along the anterior-posterior axis, width along the dorsal-ventral axis. Depth is the distance between lateral limits and was determined by direct mensuration of transverse sections or by counting the number of the sagittal sections comprising the total gland and multiplying by the thickness of the sections. It was not possible to obtain cell differentials and dimensional determinations for all pituitary glands examined.

Observations

A. Sexually Mature Platyfish

1. Morphology

The hypophysis of *Xiphophorus maculatus* is suspended from the diencephalon by an infundibular stalk immediately posterior to the optic chiasma. There is no sella turcica comparable to that found in mammals; the gland lies just above, but separated from, a slight depression in the parasphenoid bone. The pituitary is ovoid and compressed dorsoventrally. The gland has a mean anterior-posterior length of 472.9 micra, mean width of 178.3 micra and a mean depth of 376.0 micra. Male glands are smaller than those of females, but significantly so for mean depth only (see Table II). In ventral aspect, the gland gradually tapers caudally from the rounded anterior end. The dorsal surface of the pituitary is concave; ventrally it is slightly convex.

The short, thick-walled hollow infundibular stalk forms a lumen which is continuous with the third ventricle. The lumen narrows as it enters

TABLE II. TOTAL GLAND MEASUREMENTS (IN MICRA)

	Length			Width			Depth		
	Mean	S.E.	No. Animals	Mean	S.E.	No. Animals	Mean	S.E.	No. Animals
Mature Female	478.5	20.2	11	189.0	11.5	12	412.0	21.4	12
Mature Male	465.1	12.0	8	164.1	20.4	9	328.0	13.8	9
Mature Male & Female	472.9	12.0	19	178.3	10.1	21	376.0	17.0	21
Castrate Male	576.7	14.2	7	249.5	11.6	6	511.8	25.8	6
Gravid Female	543.2	35.4	4	213.3	24.7	4	475.5	41.5	4
Thyroid Tumor	512.7	17.6	6	223.2	6.9	6	463.1	12.1	7
Tumor Control	433.2	27.9	6	143.2	17.1	6	342.5	19.8	6
Melanoma	457.0	27.6	7	235.7	27.2	7	336.0	22.8	7
Melanoma Control	422.3	13.0	3	180.0	8.4	4	313.3	16.8	3

the mid-dorsal region of the hypophysis and extends into the posterior portion of the gland as the hypophysial recess. The pituitary gland is completely enveloped by a delicate connective tissue capsule.

The hypophysis (Plate I, fig. 1) is composed of four regions: pro-adenohypophysis, meso-adenohypophysis, meta-adenohypophysis and neurohypophysis, according to the terminology proposed by Pickford & Atz (1957). The pro-adenohypophysis, the most anterior portion of the organ, is bounded posteriorly by a very thin connective tissue septum that separates it from the meso-adenohypophysis immediately posterior to it. The meso-adenohypophysis ("Übergangsteil" in the older literature) is contained ventrally by the capsule, posteriorly by the meta-adenohypophysis and dorsally by the neurohypophysis. The meta-adenohypophysis constitutes the posterior part of the gland. Its delineation from the meso-adenohypophysis can be accomplished only by identification of its characteristic cell types. The neurohypophysis occupies the mid-dorsal region of the gland and forms a continuation of the stalk. Projections from it penetrate all regions of the adenohypophysis.

2. Histology and Cytology

The description that follows holds true for both male and female platyfish; no sexual dimorphism in the pituitary is evident.

a. Pro-adenohypophysis

The pro-adenohypophysis may be readily identified by several salient characteristics in addition to its anterior position and relatively large size. It is frequented by vascular channels that are considerably wider than capillaries and may suitably be termed sinusoids. The pro-adenohypophysis is populated by two cell types, carminophilic acidophils, which predominate, and chromophobes. These cells are closely packed and exhibit no particular arrangement except for a distribution of the acidophils according to size. These cells are generally smaller at the anterior portion of the pro-adenohypophysis and larger posteriorly. Morphologically the larger and smaller cells are similar. Chromophobes, in addition to their general dispersion throughout the pro-adenohypophysis, form a peninsula of cells along the anterior side of the connective tissue septum and extend between the lateral portions of the gland. This chromophobic wedge is several cells wide dorsally and tapers as it follows the contour of the posterior boundary of the pro-adenohypophysis ventrally.

Pro-adenohypophysial acidophils are round or oval in shape with eccentric nuclei (Plate I, fig. 2). They range from 6.0 to 8.0 micra in length, 3.8 to 6.3 micra in width and have a mean nuclear length of 4.4 micra. Generally they stain intensely with azocarmine, although in a few instances peripheral cells exhibit an affinity for orange G. With ponceau-acid fuchsin of the Masson method, they are colored red to orange-red. Because the large coarse granules are so closely packed, the cytoplasm oftens appears to be homogeneous rather than granular. Nuclei generally are rounded but may be oval. The disposition of chromatin material shows considerable variation; it may be in fine or coarse gran-

ules, centrally clumped, or widely dispersed in the karyoplasm. The chromatin usually stains with acid fuchsin and azocarmine, but it often shows an affinity for anilin blue. A clear area adjacent to the nuclei, presumably the negative image of the Golgi apparatus, is usually in evidence. Nucleoli consistently show an acidophilic (azocarmine and acid fuchsin) staining reaction.

Scattered among the acidophils are the chromophobes (length, 4.0 to 6.0 micra; width, 3.0 to 5.0 micra; mean nuclear length, 3.5 mirca). They are characterized by a modicum of light blue- or gray-staining cytoplasm. A central nucleus, with a heavily stained cyanophilic membrane, encloses scattered chromatin that stains with anilin blue. The wedge-like area, previously described, is comprised of closely packed polymorphic chromophobes.

b. Meso-adenohypophysis

In mid-sagittal section, the meso-adenohypophysis may readily be separated into a dorsal region that contains both acidophils and cyanophils, and a ventral cyanophilic zone. The dorsal region is pervaded by fine projections of neurohypophysial tissue that divide it into irregularly shaped islets of closely packed cyanophils and acidophils (Plate I, fig. 3). The ventral region consists of a less closely packed aggregate of cyanophilic cells. In transverse sections, the dorsal region caps the neurohypophysis and is in turn girdled by the ventral region. Four cell types may be distinguished in the meso-adenohypophysis: acidophils, two types of cyanophils, and chromophobes.

Acidophils (length, 5.0 to 8.7 micra; width, 3.5 to 5.3 micra; nuclear length, 4.1 micra) are generally round or oval although pyramidal-shaped cells are sometimes present. They are coarsely granular, and localized aggregates frequently give the cytoplasm a splotched appearance. With critical differentiation in Heidenhain's azan technique, these granules appear orange. In this method one overstains with azocarmine, differentially decolorizes and then applies the anilin blue-orange G mixture. Those acidophils that have been decolorized (*i.e.*, exhibit a lesser affinity for the azocarmine) will now accept the orange G. For this reason meso-adenohypophysial acidophils occasionally appear tinted with red and infrequently are entirely carmine colored. With Masson's technique, the acidophils are invariably red-orange and cannot be distinguished tinctorially from the acidophils of the pro-adenohypophysis. Round to oval nuclei are displaced peripherally, usually toward one end of the long axis or toward the basal end of the pyramidal-shaped cells. Chromatin material is variable in size and location. It most often accepts anilin blue but may sometimes be colored red or orange with the other acid dyes. Nucleoli are not always demonstrable.

Two classes of cyanophils can be distinguished by their morphology and their position in the meso-adenohypophysis. It is, however, impossible to differentiate between these cyanophils by means of staining intensity with anilin blue. The cyanophils in the central region, that is, the ones closer to the neurohypophysis and in closer relationship to the acidophils, are spherical with a large, round, centrally located nucleus. The diameters of these cyanophils range from 3.0 to 6.0 micra, and they have a mean nuclear length of 3.8 micra. Characteristically they have a uniformly thin rim of finely granular, cyanophilic cytoplasm. The round nucleoli and fine chromatin granules exhibit an affinity for azocarmine. The peripheral cyanophils, by comparison, show little uniformity in shape and vary in size from 5.5 to 9.0 micra in length and 4.8 to 7.5 micra in width. Nuclear structure is also variable. Although their most prevalent form is round or oval, the nuclei may be elongate, constricted or appear slightly twisted. Red nucleoli are found in varying chromatin substance. The cytoplasmic granules of the ventral cyanophils vary considerably from cell to cell and are larger than those of the dorsal cyanophils. Small cytoplasmic vacuoles are often seen. A unique feature of the majority of these cyanophils is the presence of orange or red spherical hyaline droplets in the cytoplasm. These cytoplasmic inclusions vary in size and number per cell.

The chromophobic elements of the meso-adenohypophysis are not as prevalent as their counterparts in the pro-adenohypophysis, but they are very similar in structure.

c. Meta-adenohypophysis

The meta-adenohypophysis is the most posterior region of the platyfish pituitary, and it is extremely variable in extent and cellular arrangement. It also encompasses more neurohypophysial tissue than any other region. The two cell types of the meta-adenohypophysis (Plate I, fig. 4) are best demonstrated in glands fixed in Elftman's chrome alum fluid. One cell type is a cyanophil but the other cannot be classified on the basis of its staining reaction.

Cyanophilic cells are round or oval with similarly shaped nuclei (length, 5.0 to 7.4 micra; width, 3.0 to 6.0 micra; mean nuclear length, 4.0 micra). The cytoplasmic granules, which are comparatively large, are subject to variation in color with Heidenhain's azan technique, depending on the method of fixation. With formal-sublimate the granules are purple, with chrome alum fluid they assume a very deep blue hue, and with

Helly's solution they are a more reddish-purple. Large aggregates of red-staining chromatin occupy the center of the nucleus. The nucleolus also takes azocarmine stain.

The second cell type of the meta-adenohypophysis exhibits inconsistent staining reactions. It occurs in nests and is generally spindle-shaped, but may show considerable variation in form (length, 5.0 to 8.0 micra; width, 2.0 to 5.5 micra). The nuclei (average length, 4.1 micra) are bizarre, with inconspicuous nucleoli. Generally the cytoplasm appears to be agranular and translucent. The staining reaction of these cells is very erratic, *i.e.*, they are non-selective for any dyes. Pastel hues, shades of green and brown and odd mixtures of red, orange and blue are evident in any small group of them. Their cellular and nuclear membranes also lack definition.

d. Neurohypophysis

The neurohypophysis occupies a sizable portion of the gland and possesses many interesting and distinctive features. The typical impression is one of a highly branched or loosely tangled network of fine fibroid material that is continuous with the infundibular stalk and extends into the glandular epithelium. This is generously interspersed with granular material, large irregularly shaped amorphous masses and large nuclei.

The coarse granular material, usually considered to be neurosecretory, stains red with azocarmine and a muddy, light orange-red with ponceau-acid fuchsin. The heaviest concentration of it is consistently found in the neurohypophysial region adjacent to the meta-adenohypophysis where the granules may be so numerous that the tangled network appearance of the neurohypophysis is obscured (Plate III, fig. 1). The granules are scarce or absent in the region of the pro-adenohypophysis, but become more numerous posteriorly. Neurosecretory granules are concentrated adjacent to, but never in, the vascular channels.

The amorphous masses, or "Herring bodies," are similar to the neurosecretory granules in their staining response and are located in the mid-dorsal region. The smaller ones are uniformly colored red, but in the larger masses a darker peripheral surrounds a lighter central area.

The rounded nuclei, which are characteristic of the neurohypophysis, are relatively large (about six micra). They possess a heavy nuclear membrane which encloses a carminophilic nucleolus and chromatin particles. The cytoplasm is not demonstrable.

A lamina of ependyma cells lines the neurohypophysial area bordering the infundibular cavity and the hypophysial recess. These cells have a large nucleus with a modicum of cytoplasm which extends as finger-like processes into the lumen.

3. Observations with periodic acid-Schiff and aldehyde fuchsin methods.

a. Pro-adenohypophysis

Application of the periodic acid-Schiff (PAS) and the aldehyde fuchsin techniques indicates a general negative response within the pro-adenohypophysis. There is, however, a small PAS-positive sphere, smaller than a nucleolus, just outside the nuclear membrane. These positively-stained granules have been described in the stickleback and referred to as "juxta-nuclear granules" by Van Mullem (1958).

b. Meso-adenohypophysis

All PAS-positive cells of the meso-adenohypophysis are also cyanophilic. The strongest concentration of PAS-positive material is found in the peripheral meso-adenohypophysis with less in the central portion (Plate III, fig. 2). These areas correspond respectively to the peripheral layer of cyanophils and to the cyanophils of the mid-region. Ventral cyanophils contain numerous large, PAS-positive granules, small, clear areas presumably vacuoles, positive colloid droplets and non-staining nuclei. Two cell types can be identified in the mid-region; cyanophils with fine PAS-positive material and acidophils that are negative. As with the pro-adenohypophysial acidophils, a single PAS-positive granule lies adjacent to the nuclear membrane. In the meso-adenohypophysis, as in all other parts of the platyfish hypophysis, blood cells and blood vessels cannot be demonstrated with Schiff's reagent.

In Halmi's (1952) method, light green and aldehyde fuchsin differentiate gonadotrophs from thyrotrophs in the rat and mouse, and orange G demonstrates acidophils. In the platyfish pituitary, however, purple granular substance (aldehyde fuchsin-positive) is found in all cells that are PAS-positive (Plate III, figs. 1 & 2). The colloid droplets in the peripheral cyanophils of the meso-adenohypophysis do not accept aldehyde fuchsin; they do, however, stain with orange G. This affinity for orange G is also characteristic for nucleoli, red blood cells and the acidophils of the meso-adenohypophysis. Cyanophils of the dorsal meso-adenohypophysis may contain clumped purple granules in a homogeneous green cytoplasm.

Elftman (1959) reports that aldehyde fuchsin following oxidation demonstrates both thyrotrophs and gonadotrophs in mammalian pituitaries and that without oxidation, only the cells concerned with synthesis of thyrotrophin are

purple. In the pituitaries of sexually mature platyfish, all cyanophils stain purple with or without prior oxidation. The oxidative process merely increases the intensity of the aldehyde fuchsin response.

c. Meta-adenohypophysis

The cyanophils of the meta-adenohypophysis are colored light red with the PAS technique and purple with Halmi's aldehyde fuchsin. As with the azan method, agranular cells of the meta-adenohypophysis show no consistent staining reaction with PAS and aldehyde fuchsin procedures.

d. Neurohypophysis

The neurosecretory granules and Herring bodies do not respond to the periodic acid-Schiff method but are dramatically demonstrated with aldehyde fuchsin (Plate III, figs. 1 & 2). Few aldehyde fuchsin-positive granules may be identified in the ependyma cells lining the infundibular cavity.

4. Differential Cell Counts

Differential cell counts of sexually mature male and female platyfish do not show any sexual dimorphism *i.e.*, male and female counts were not significantly different. The mean percentages for both sexes were: acidophils, 50.0%; cyanophils, 20.0%; chromophobes, 30.0% (see Table VI).

B. Pituitary Structure in Relation to Age

1. The Hypophysis in Young Forms (One to Eight Weeks Old).

In contrast to the hypophysis of mature fish, the glands of one-week-postpartum specimens are ellipsoidal in shape and lack the dorsal depression and ventral convexity. The immature gland is held against the brain by a very wide, thin-walled stalk and lies just dorsal to the parasphenoid bone (Plate II, fig. 1).

In mid-sagittal section, the pituitary gland is composed of almost equal areas of adenohypophysis and neurohypophysis. The adenohypophysis exhibits two clearly separated areas: an anterior portion, occupying about two-thirds of the gland's total length, and a posterior third, the meta-adenohypophysis. The anterior portion, in turn, may be further sub-divided by cell type into an anterior two-thirds composed of carminophilic acidophils representative of the pro-adenohypophysis, and a posterior third populated by groups of mixed acidophils and cyanophils and comparable to the adult meso-adenohypophysis. In one-week-old fish, the wedge of chromophobic cells and the connective tissue septum, which separate the pro- and meso-adenohypophysis in adults, are dorsal to the pro-adenohypophysis and form the boundary between this region and the neurohypophysis. Moreover, the wedge of cells is quite small and the connective tissue septum appears to end blindly in the mid-dorsal region.

The more extensive anterior acidophilic area is composed of large cells with coarse carminophilic granules and a large round or oval nucleus with a prominent nucleolus. Dispersed among these acidophils are some chromophobes that stain light blue or are colorless.

Posterior to these anterior acidophils is the region that encompasses cyanophils and acidophils in varying proportions and is comparable to the adult meso-adenohypophysis. The cyanophils are large and circular with unevenly distributed fine cytoplasmic granules. These cells are structurally similar to, and probably identical with, the central cyanophils of the mature platyfish. The acidophils are pyramidal or spherical in shape and contain large, red-orange granules. The peripheral cyanophils (ventral in mid-sagittal section), characteristic of the adult pituitary, are not present at this stage of development. Instead, this area contains a few chromophobes (Plate II, fig. 3).

The meta-adenohypophysis, directly ventral to the neurohypophysis, is a dense aggregate of typical purple cyanophils and limited numbers of spindle-shaped cells with little affinity for azocarmine.

The neurohypophysis of both week-old fish and adult is essentially similar, but it occupies most of the dorsal mass of the immature pituitary and lacks the extensive arborization found in the adenohypophysis of the adult. In the region of the hypophysial recess of week-old fish, the cells exhibit a thin regular rim of cyanophilic cytoplasm. The large nuclei, characteristic of the adult neurohypophysis, are absent.

The developmental picture that is presented by the pituitary glands of males and females up to four weeks of age remains essentially unchanged, although there is a perceptible increase in hypophysial size with the increase in body length (see Table IV). Acidophils are still the dominant cell type of the gland. A small band of chromophobes, about one to two cells in depth along the ventral periphery of the meso-adenohypophysis, represents the corresponding cyanophilic region in the adult gland. With increase in age, the nuclei of these chromophobes show a progressional increase in volume. During the initial two- to four-week period of development, the meta-adenohypophysis proliferates posteriorly and dorsally from its original ventral position. Neurohypophysial growth is most obvious in the region of the meso-adeno-

TABLE III. GLAND REGION MEASUREMENTS (IN MICRA)

			Mature Female	Mature Male	Mature Male & Female	Castrate Male	Gravid Female	Thyroid Tumor	Tumor Control	Melanoma	Melanoma Control
PRO.*	Length	Mean	223.4	198.0	214.9	213.1	207.3	199.3	171.5	212.1	181.5
		S.E.	14.0	16.0	10.7	6.5	16.8	8.1	15.7	25.0	8.4
		No. Animals	10	5	15	7	4	6	6	7	4
	Width	Mean	172.1	155.0	166.4	213.0	242.5	225.8	166.7	250.1	204.0
		S.E.	9.0	16.0	10.7	17.4	28.0	13.2	11.8	24.0	10.4
		No. Animals	10	5	15	7	4	6	6	7	4
MESO.	Length	Mean	188.1	171.8	180.7	293.7	233.0	268.7	166.2	178.7	153.7
		S.E.	27.8	15.5	14.2	19.2	24.1	10.9	22.7	18.7	8.8
		No. Animals	6	5	11	7	4	6	6	7	3
	Width	Mean	115.1	88.3	103.7	181.3	146.5	160.5	101.7	164.7	120.7
		S.E.	12.8	14.9	10.2	12.5	21.3	15.1	6.2	16.6	5.9
		No. Animals	6	3	9	7	4	6	6	7	3
META.	Length	Mean	109.8	126.2	116.4	159.8	155.3	122.8	148.7	102.7	147.3
		S.E.	8.1	8.0	7.0	24.7	26.9	20.1	14.8	7.6	15.4
		No. Animals	6	4	10	5	4	6	6	7	4
	Width	Mean	138.7	124.7	134.4	137.6	154.3	135.3	114.5	126.0	143.0
		S.E.	14.1	27.0	11.6	13.8	29.5	14.1	5.5	11.0	14.9
		No. Animals	9	4	13	5	4	6	6	7	4

*Abbreviations used in the following tables:

PRO.	Pro-adenohypophysis	No.	Number	NUC.	Nucleus
MESO.	Meso-adenohypophysis	ACIDO.	Acidophil	%	Percent.
META.	Meta-adenohypophysis	CYANO.	Cyanophil		
S.E.	Standard error	'PHOBE.	Chromophobe		

TABLE IV. PITUITARY DIMENSIONS AND BODY LENGTH OF YOUNG FISH
(Gland Values in Micra)

		Age (in Weeks)					
		1	2	3	4	6	8
Average Total Body Length (mm.*)		10.0	12.0	15.0	17.0	19.5	22.3
	No. Animals	4	4	4	4	4	4
Total Gland	Length	200	257	255	299	359	
	S.E.	13.4	4.6	10.3	4.5	7.9	
	No. Animals	3	3	8	4	3	
	Width	52	73	80	95	103	
	S.E.	2.9	1.7	4.1	7.0	4.2	
	No. Animals	3	3	7	4	3	
	Depth	136	163	182	206	232	
	S.E.	11.8	6.3	11.5	9.8	4.2	
	No. Animals	3	3	7	4	3	
PRO.	Length				158	204	
	S.E.				13.3	21.8	
	No. Animals				2	3	
	Length+meso.	147	193	209	233	284	
	S.E.	9.6	2.6	12.4	8.2	15.5	
	No. Animals	3	3	7	4	3	
	Width	42	54	66	73	89	
	S.E.	2.6	4.6	4.1	9.5	5.0	
	No. Animals	3	3	7	4	3	
MESO.	Length				80	109	
	S.E.				10.9	14.7	
	No. Animals				3	3	
	Width	25	38	43	49	57	
	S.E.	1.7	1.3	1.2	4.5	3.8	
	No. Animals	3	3	7	4	3	
META.	Length	45	75	63	70	74	
	S.E.	8.4	2.1	3.3	2.0	5.0	
	No. Animals	3	3	7	4	3	
	Width	11	26	22	39	59	
	S.E.	1.7	2.1	3.6	4.8	0.9	
	No. Animals	3	3	6	4	3	

*Snout to tip of caudal fin.

hypophysis. Septa of neurohypophysial tissue proliferate into the gland and divide this region into characteristic meso-lobules.

At six weeks of age, there are definite indications of a separation between the pro- and meso-adenohypophysis. Although the chromophobic wedge of cells and the connective tissue septum are still essentially dorsally placed, the beginning of their ventral proliferation can be seen between the pro-adenohypophysis and meso-adenohypophysis. This progression is more marked at eight weeks of age when the meso- and pro-adenohypophysis are more clearly separated. The meso-adenohypophysis shows extensive growth along all axes. To a lesser extent, the pro-adenohypophysis has extended anteriorly and dorsally. As a result of this increase in glandular tissue, the neurohypophysis becomes relatively smaller and occupies a more central position.

Cytologically, the most interesting change involves the cells of the peripheral meso-adeno-

hypophysis. In six-week-old platyfish, the first appearance of a few granulated cyanophils occurs in the still predominately chromophobic zone. These cells continue to be characterized by large nuclei and little cytoplasm. In mid-sagittal sections of eight-week-old fish, the ventral zone of the meso-adenohypophysis has noticeably increased in mass (Plate II, figs. 2 & 4). Cyanophilic cells with denser granulation are much more in evidence, and these are small facsimiles of cells from corresponding areas of the mature gland.

At six weeks postpartum, the cyanophils of the central meso-adenohypophysis are more fully granulated and resemble the corresponding cells in adults. Carminophilic acidophils of the pro-adenohypophysis are large and fully granulated; they contrast with the less heavily granulated acidophils of the meso-adenohypophysis. Both cells, however, contain large nuclei with prominent nucleoli. In six- to eight-week-old fish, the meta-adenohypophysis shows a progressive degranulation of the purple cyanophils.

Between the first and sixth week of development, all glandular measurements have approximately doubled (Table IV). During this period there are no significant changes in acidophil and cyanophil ratios (see Table VI). Chromophobes, however, show a slight but significant increase (P equals less than 0.05). On the other hand, the percentage of acidophils in the pituitaries of one- to six-week-old fish remains fairly constant, but higher than the acidophil percentages of mature glands. No mitotic figures were ever recognized during this development.

2. Pituitary Glands of Aging Female Platyfish (28 to 33 Months Old).

The animals utilized for studies of the effects of aging on the pituitary gland were aged and control platyfish of the Grijalva strain selected from several laboratory aquaria.

The aged pituitary is suspended by a thick-walled, wide stalk and is surrounded by a thick connective tissue capsule. In mid-sagittal section the gland appears rounded because of an obvious increase in the dorsal-ventral axis (width) of each region of the gland. With this increase in width, the pro- and meta-adenohypophysis seem to have become compressed along their anterior-posterior axis (Plate IV, fig. 1). The pro- and meso-adenohypophysis and neurohypophysis are the regions that exhibit the most noticeable changes from the normal.

The pro-adenohypophysis of aged females is comprised of a large ventral chromophobic area not found in normal younger fish, and a carminophilic area dorsal to it. Cell counts in senile fish (Table VI) reflect this chromophobia. Nuclei of the chromophobes are irregular in shape and have a relatively thick membrane. Nucleoli show considerable variation. As indicated in the table of cell dimensions, carminophils are larger (Table V) and they are richly granulated with vivid, dark carmine inclusions.

Characteristically, the meso-adenohypophysis has a wider peripheral band of cyanophils. This increase in area represents cellular hypertrophy (Table V, P=less than 0.05) rather than a cell increment. The cytoplasm of these larger cyanophils is usually pale blue and hyaline. In cells with granular inclusions, the extent of granulation is highly variable. Some vacuoles and an abundance of red- or orange-staining bodies are contained in the cyanophils of the peripheral meso-adenohypophysis. Nuclear size varies and the nuclei contain fine cyanophilic chromatin that surrounds a conspicuous nucleolus. The cyanophils of the central meso-adenohypophysis significantly decrease in size (P=0.05, see Table V) as also do their nuclei. Cytoplasmic appearance varies considerably but generally the cells display a loss of granular material. Vacuolation is infrequent. The acidophils of the meso-adenohypophysis of old glands show no apparent morphological changes.

As revealed in sagittal sections, the neurohypophysis of glands from senile fish occupies a much greater area and its embranchment is more marked. There is a definite increase in the size of the Herring bodies.

C. Effects of Gravidity on the Pituitary of Platyfish

Fish were taken from laboratory stock and if found gravid on routine examination, were utilized for this phase of the investigation. No record of the advancement of gestation was known at the time of sacrifice. Nevertheless, in the seven gravid platyfish examined, certain consistencies prevailed in the histology and cytology of their pituitary glands.

The meso-adenohypophysis of gravid fish is wider and longer than it is in normal females (see Table III). This increase in mass is brought about by hypertrophy and hyperplasia of the peripheral cyanophils and hyperplasia, without hypertrophy, of the acidophils in the central region (Plate V, figs. 1 & 2; Table V). The cyanophil count increases from 20.0% in normal females to 29.0% in gravid individuals. Often, the cyanophils of the peripheral region will extend as a thin band ventrally and posteriorly around the meta-adenohypophysis. The cyanophils of the central zone exhibit no gross variations from those in non-gravid females. Peripheral cyanophils contain many large, spherical, reddish col-

loid droplets, and clear vacuoles in an agranular-appearing cytoplasm. Round nuclei enclose large red nucleoli. Acidophils are the predominant cell of the dorsal meso-adenohypophysis. They are round or oval in form and have similarly shaped nucleoli. Their coarse, red-orange granulation makes them readily indentifiable.

Other parts of the pituitary gland are not noticeably altered in gravid platyfish.

D. Effects of Castration on the Pituitary of Male Platyfish

In castrated male platyfish, the hypophysis is always characterized by a marked increase in total size (mean dimensions: length, 567.7 micra; width, 249.5 micra; depth, 511.8 micra). Although the size of the pro- and meta-adenohypophysis is essentially unchanged, the meso-adenohypophysis increases markedly along all its axes (Table III). Very often the meso-adenohypophysis encroaches upon the ventral and posterior meta-adenohypophysis with a thin border of ventral meso-adenohypophysial cyanophils.

The cyanophil is the predominate type of cell in the meso-adenohypophysis of castrate males. Differential cell counts corroborate this increase in cyanophils (see Table VI). The castrate pituitary invariably exhibits an increase in the width of the peripheral cyanophil cell layer (Plate III, fig. 3). Although all types of cyanophils are affected by gonadectomy, only the cyanophils of the peripheral layer are conspicuously vacuolated. In the central meso-adenohypophysis, the small islets of cells, formed by the septa of neurohypophysial tissue in the normal gland, are less obvious; instead, large masses of cells constitute this region. Acidophils are oriented in small groups along the neurohypophysial border and as isolated cells scattered among the central cyanophils. In addition, there appears to be an increased amount of vascularity.

The peripheral cyanophils of the meso-adenohypophysis exhibit pronounced hypertrophy and hyperplasia (Table V). It is therefore surprising that no mitotic figures were ever observed. The majority of the peripheral cyanophils show varying degrees of cytoplasmic degranulation and inflated nuclei and nucleoli. Vacuoles vary in magnitude and number and are evident in the majority of these cyanophils. They generally stain a paler blue than corresponding cells of normal fish, and cell delineation is less pronounced. In many castrate pituitaries, cells that fit the description of mammalian "castration cells" were observed. These cells are not present in large numbers but are readily identifiable. Their most prominent characteristics are the large, pale blue, agranular vacuole, the thin ring of cytoplasm containing dark granules, and the nucleus displaced to the periphery, all of which give the cell the signet-ring appearance reminiscent of its mammalian counterpart (Plate III, fig. 4).

The mid-dorsal cyanophils are irregularly shaped (normally these cells are smooth spheres) and only slightly hypertrophied (Table V). The granules appear as dispersed light blue floccules. Vacuolation is usually absent. Nucleoli are more prominent in these cells than in their counterparts in unoperated fish.

Periodic acid-Schiff and aldehyde fuchsin techniques confirm the observations made on azan stained castrate pituitaries. The amount of "positive" material was reduced, corresponding to the degranulation that occurs in both cyanophil cell types of the meso-adenohypophysis. This degranulation was especially obvious in the cells of the peripheral zone. In contrast, the response of the cyanophils in the meta-adenohypophysis to the aldehyde fuchsin and the PAS techniques remains unchanged.

The acidophils of the meso-adenohypophysis are essentially the same as those in the gland of intact fish.

In the pro- and meta-adenohypophysis, and neurohypophysis, there are no significant deviations from the unoperated controls.

E. The Pituitary in Tumor-bearing Fish

1. Platyfish with Heterotopic Thyroid Tumors

Pituitaries from platyfish with heterotopic thyroid tumors, in addition to being larger than normal, can be readily identified macroscopically by a characteristic bulging of the meso-adenohypophysis that girdles the mid-region of the gland (Text-fig. 1B). Microscopically it can be seen that the marked increase in the dimensions of the meso-adenohypophysis accounts for the increased total volume of the pituitary (Tables II & III; Plate IV, fig. 2). Peripheral and central cyanophils are clearly delineated. Peripheral cyanophils are confined to the protuberant region where they occur as loose aggregates of dark blue cells (Plate IV, fig. 3). Cells of the central meso-adenohypophysis, located between the peripheral cyanophils and the neurohypophysis, comprise two types: closely packed, rounded cyanophils that are the predominant type, and orange acidophils that occur singly or in small groups along the neurohypophysis. These clusters of dorsal meso-adenohypophysial cells are much larger than those in the normal adult.

The cyanophils of the central region show hypertrophy and hyperplasia. Measurements indicate that both nuclei and cell size are involved in the hypertrophy (Table V). No mitotic fig-

TABLE V. CELLULAR DIMENSIONS AND NUCLEAR LENGTH

(Cell dimension values represent the mean products of cell length × cell width in micra. Mean nuclear length given in micra)

	Mature Female	Mature Male	Mature Male & Female	Castrate Male	Gravid Female	Thyroid Tumor	Tumor Control	Melanoma	Melanoma Control	Old Females	Old Controls
PRO.											
ACIDO.											
Mean	35.1	35.8	35.3	38.6	35.0	38.5	35.6	49.2	37.6	45.4	33.2
S.E.	2.0	1.7	1.3	1.5	4.0	4.3	3.3	2.8	2.0	2.9	1.2
Nuc.	4.2	4.7	4.4	4.6	4.8	4.8	4.4	4.9	4.2	4.6	4.5
S.E.	0.1	0.2	0.1	0.1	0.2	0.1	0.3	0.3	0.2	0.1	0.2
No. Animals	10	5	15	7	3	6	6	6	4	6	5
'PHOBE.											
Mean	18.9	20.4	19.5								
S.E.	2.4	3.9	2.0								
Nuc.	3.4	3.5	3.5								
S.E.	0.2	0.3	0.1								
No. Animals	8	5	13								
MESO.											
ACIDO.											
Mean	32.8	26.4	31.2	27.4	30.0	35.0	28.8	46.0	38.5	28.6	28.8
S.E.	2.8	7.2	2.4	0.5	3.4	1.6	3.7	3.1	6.0	3.2	3.8
Nuc.	4.2	3.7	4.1	3.8	4.6	4.3	3.9	4.7	4.3	3.6	4.1
S.E.	0.1	0.1	0.1	0.1	0.3	0.2	0.1	0.1	0.4	0.1	0.7
No. Animals	9	3	12	7	4	6	6	7	4	5	4
*CYANO.											
Mean	24.4	23.4	24.0	33.3	22.3	62.4	22.9			21.1	28.0
S.E.	1.0	3.4	1.1	1.9	1.3	4.1	1.9			2.9	0.8
Nuc.	3.9	3.8	3.8	4.2	4.0	5.4	3.8			3.4	4.6
S.E.	0.1	0.1	0.1	0.2	0.1	0.2	0.3			0.3	0.1
No. Animals	10	5	15	7	4	6	6			5	5

*Central cyanophils.

TABLE V. CELLULAR DIMENSIONS AND NUCLEAR LENGTH (Contd)

(Cell dimension values represent the mean products of cell length × cell width in micra. Mean nuclear length given in micra)

	Mature Female	Mature Male	Mature Male & Female	Castrate Male	Gravid Female	Thyroid Tumor	Tumor Control	Melanoma	Melanoma Control	Old Females	Old Controls
MESO.											
†CYANO											
Mean	39.6	32.7	37.2	54.6	52.8	26.6	35.0			50.7	36.6
S.E.	3.9	2.9	2.2	3.3	2.4	1.3	1.9			6.0	2.9
Nuc.	4.3	4.1	4.2	4.5	4.3	3.8	4.5			4.2	4.0
S.E.	0.1	0.1	0.1	0.2	0.3	0.1	0.1			0.3	0.3
No. Animals	10	5	15	7	4	6	6			6	5
'PHOBE											
Mean	21.8	19.4	21.1								
S.E.	2.4	4.6	2.0								
Nuc.	3.9	4.0	3.9								
S.E.	0.3	0.4	0.2								
No. Animals	7	3	10								
META.											
CYANO.											
Mean	29.1	31.2	29.8					34.9	29.0	25.6	27.1
S.E.	3.1	2.9	1.9					2.1	2.0	3.1	3.7
Nuc.	4.1	3.8	4.0					4.7	4.3	3.6	2.9
S.E.	0.2	0.2	0.1					0.1	0.4	0.1	0.1
No. Animals	10	5	15					6	4	4	3
"TYPE II"											
Mean	25.3	22.4	24.1								
S.E.	2.6	3.1	1.5								
Nuc.	4.3	3.8	4.1								
S.E.	0.3	0.2	0.1								
No. Animals	7	5	12								

†Peripheral Cyanophils.

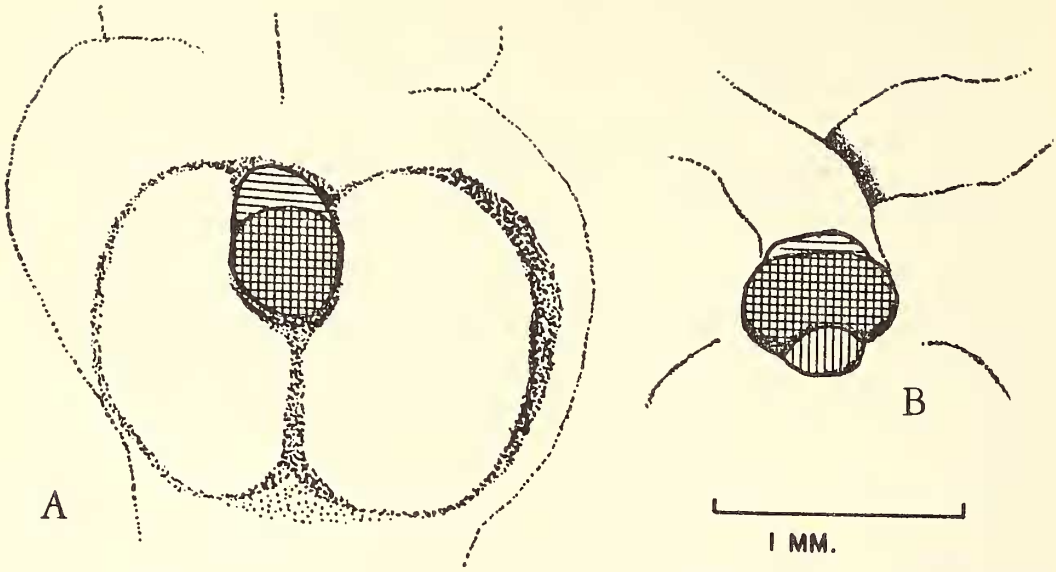

TEXT-FIG. 1. **A.** Normal pituitary gland in ventral aspect with associated brain structures (stippled lines). Pro-adenohypophysis (anterior) represented by horizontal lines; squares indicate combined meso- and meta-adenohypophysis. Camera lucida drawing. **B.** Pituitary gland of a playfish with a thyroid tumor. Note bulging of meso-adenohypophysis (squares). Horizontal lines represent the pro-adenohypophysis (just posterior to the optic chiasma); vertical lines represent the meta-adenohypophysis. Camera lucida, ventral aspect.

ures were ever observed. Red nucleoli are also larger and more prominent. There is a very marked dimunition of cytoplasmic granules, and this is confirmed by a diminished aldehyde fuchsin reaction (Plate IV, figs. 3 & 4). Small vacuoles appear infrequently. Acidophils of the central meso-adenohypophysis of tumorous fish are larger; however, statistical analysis indicates that this is not a significant difference. These acidophils are also less regular in shape.

Peripheral cyanophils of the meso-adenohypophysis are smaller (P=less than 0.01), more irregularly shaped, and more intensely cyanophilic and aldehyde fuchsin-positive. The intensely staining, heavily granulated cytoplasm contains varying numbers of red or orange, aldehyde fuchsin-negative droplets, as in the normal fish. Quite characteristic are the nuclei; they are smaller than normal, less uniform in shape, more condensed, and have smaller nucleoli.

In one specimen, a fish in which the neoplasm appeared to be confined to the gill region, the protuberant area of the meso-adenohypophysis was less obvious and hypertrophy of the central cyanophils was evident without distinct hyperplasia.

The other three regions of the pituitary show no marked histological modifications from the picture presented by glands of the normal fish.

2. Hybrids with Melanotic Tumors

The most prevalent and consistent features of the melanomatous fish hypophysis are a highly significant (P=0.01) hypertrophy of the pro-adenohypophysial acidophils and a dramatic hyperplasia of the meso-adenohypophysial acidophils.

The pro-adenohypophysial carminophils in fish with melanoma may assume one or the other of two cytological states. In some glands, all the acidophils are very much degranulated except for those cells that are adjacent to the blood vessels. In other glands, all the acidophils are distended with numerous closely packed coarse granules. Both forms of carminophils have a large nucleus and a prominent nucleolus.

So marked is the acidophil hyperplasia in the meso-adenohypophysis that at low magnification it appears as a wide, bright, orange-yellow band extending between the pro- and meta-adenohypophysis (Plate V, fig. 4). These cells are almost always fully granulated. The majority have a homogeneous-appearing granulation; occasionally coalescence of the granules seems evident. Cell and nuclear shapes are polymorphic. The prominent nucleolus is variable in size. Although the acidophils of the mid-region are larger on the average than those of normal animals, the large range of values precludes any

TABLE VI. DIFFERENTIAL CELL COUNTS (WHOLE GLANDS)

	Acido.			Cyano.			'Phobe.			Mean No. Counted Per Gland
	Mean %	S.E.	No. Animals	Mean %	S.E.	No. Animals	Mean %	S.E.	No. Animals	
Mature Males & Females	50.0	0.7	9	20.0	0.7	9	30.0	0.9	9	1190
Mature Males	49.3	0.9	3	20.0	2.1	3	30.7	1.3	3	1199
Mature Females	50.3	1.1	6	20.0	1.1	6	29.7	1.4	6	1186
Castrate Male	40.6	0.6	7	32.7	0.8	7	26.7	0.9	7	1436
Thyroid Tumor	44.6	0.9	5	30.0	0.7	5	25.4	0.5	5	1287
Tumor Control	47.9	1.2	7	21.1	0.6	7	31.0	1.1	7	1223
Gravid Female	48.3	1.1	4	29.0	2.3	4	22.7	2.0	4	1692
Old Female	33.8	3.9	4	26.8	4.5	4	39.4	4.8	4	941
Old Control	48.3	0.9	4	25.3	0.9	4	26.4	0.9	4	718
IMMATURE										
One Week Old	56.7	1.7	3	20.3	1.3	3	23.0	1.3	3	355
Two " "	55.7	0.4	3	19.0	0.0	3	25.3	0.4	3	566
Three " "	54.3	1.2	7	20.0	1.1	7	25.7	0.9	7	545
Four " "	53.0	2.1	3	17.4	0.4	3	29.6	2.6	3	824
Six " "	53.7	1.3	3	19.0	0.9	3	27.3	0.4	3	1130

statistical significance (*viz.*, 46.0±3.0 versus 38.5± 6.0).

Less consistent, but nevertheless quite apparent, is the increased size of meta-adenohypophysial cyanophils. Here, too, the cytoplasm is completely granulated. These cells average larger in size than the corresponding cells of normal animals, but determination of "P" values (greater than 0.05) indicates that there is no statistically significant increase. The agranular cells of the meta-adenohypophysis are round, stain light green with the azan method, and possess dense nuclei.

The variability in gland measurements (Table II) is great, but this may be explained, at least in part, by the animals used. In "M1" animals, which were produced by repeated back-crosses to the swordtail, the pituitaries resemble in gross shape the swordtail pituitary, that is, they have distinctly rounded (knob-like) anterior and posterior ends. In the "M2" strain, in which hybrid offspring were inbred, the posterior end is more tapered and thus resembles the platyfish pituitary. The only statistically significant differences in pituitary dimensions between melanomatous and normal fish are a decrease in length of the meta-adenohypophysis and an increase in the dorsal-ventral axis (width axis) of the pro- and meso-adenohypophysis (Table III) in fish with melanomas.

Discussion

A. The Pituitary in Normal, Sexually Mature Platyfish

Most investigators agree that the teleost pituitary may be differentiated into four regions—three glandular portions and a neurohypophysis—but views differ concerning the precise location of the regions, their characteristic cell types and terminology. The use of diverse histological procedures, particularly fixatives and stains designed for general use, has contributed to this confusion, because the glandular regions are usually delineated by the cells they are supposed to contain. For example, Mathews (1936) found only two glandular areas in pituitaries of *Fundulus heteroclitus*. His failure to differentiate a pro- and meso-adenohypophysis in his "transitional area" very likely resulted from his choice of eosin-azure as a stain. With aldehyde fuchsin (Halmi's method), Sokol (1961) demonstrated three glandular regions in the same species. Her descripition lends support to the present interpretation of the arrangement of hypophysial regions in *X. maculatus*.

The importance of technique is also illustrated by Bell's (1938) description of the goldfish hypophysis. He stated that the Masson-stained "pars anterior" (pro-adenohypophysis) was largely "basophilic." This is very questionable in the light of Levenstein's (1939) and Scruggs' (1939) reports in which the Heidenhain azan technique was used, and in a more recent report in which erythrosin and anilin blue were utilized (Olivereau, 1962a). All three investigators agree that the pro-adenohypophysis (our terminology) is predominately acidophilic with some basophils (cyanophils) and chromophobes. Ortman (1961) identified "dull purple basophils" in Mallory-stained pro-adenohypophyses of the closely related carp. In the present investigation, no cyanophils have been demonstrated in the carminophilic pro-adenohypophysis of *X. maculatus*.

In an investigation of Helly-fixed and Masson-stained pituitary glands of six species of poeciliids (not including *X. maculatus*), Potts (1942) reported that the pars intermedia (meta-adenohypophysis) surrounds the meso-adenohypophysis, and is contiguous with the pro-adenohypophysis. In normal platyfish, the meta-adenohypophysis never surrounds the meso-adenohypophysis, and the reverse may be true in pituitaries of castrate males and gravid females. The differentiation of the meta-adenohypophysis from the peripheral meso-adenohypophysis can be accomplished only by the identification of the characteristic cyanophils of each region. It appears that Potts did not achieve this separation of cell types; he stated that the "basophils" of the middle pars intermedia (meta-adenohypophysis) closely resemble the basophils of the "Übergangsteil" (meso-adenohypophysis).

Öztan (1961) studied platyfish pituitaries fixed with Bouin's solution containing trichloracetic acid and subjected to several suitable staining techniques. Neither the meso- nor the meta-adenohypophysis appears to have been properly differentiated, however, and as a result they were combined into a "central zone of the pars distalis." As a result of this difficulty, the pars intermedia (meta-adenohypophysis) seems to have been assigned a questionable location in the gland. According to our interpretation, Öztan's "pars intermedia" partly corresponds to the chromophobic wedge of cells adjacent to the pro-adenohypophysis; indeed, Öztan reports that these cells are chromophobic in their staining affinities. We must now account for the several cyanophil cell types described by this investigator. The position and description of her "type 2" cells correspond closely to the central meso-adenohypophysial cyanophils that we have described. On the basis of position, her "type 1" cells belong to the meta-adenohypophysis. An

examination of Öztan's chart for tinctorial properties and her description of "type 1" cells reveal the similarities between these cells and the second cell type of the meta-adenohypophysis that we have described. Öztan's "type 3" basophilic cell resembles, for the most part, our peripheral cyanophils of the meso-adenohypophysis, but she does not distinguish them from the cyanophils of the meta-adenohypophysis.

Baker-Cohen (1961) and Mac Intyre & Baker-Cohen (1961) have provided brief descriptions of the platyfish pituitary in reports primarily devoted to other aspects of fish endocrinology. Aside from their brevity, these studies illustrate the impracticability of utilizing general histological techniques for specialized pituitary analyses. Their information was derived from sections 10 micra thick of whole fish fixed in Bouin's solution or 10% formalin, decalcified in formic acid and stained with hematoxylin and eosin or with the Masson method. Only a "dark basophil" in the most anterior region, a "paler basophil" in the mid-region, and the neurohypophysis could be differentiated. These authors could not identify acidophils. It appears that the "dark basophils" of the "anterior pituitary" are actually carminophilic acidophils (with Heidenhain's) of the pro-adenohypophysis.

Exception must be taken to the statement of McManus & Mowry (1960, p. 318) that "fixation for the anterior pituitary is of some importance when enzyme activity is to be studied but it does not seem crucial in the differentiation of cell types." This statement was based on the examination of human material and is very likely only applicable to human glands. The work of Geske (1956) may be cited as evidence that the view of McManus & Mowry does not necessarily hold for the teleosts. In azan-stained, Susa-fixed pituitary glands of the guppy, *Poecilia (=Lebistes) reticulata,* Geske described a meso-adenohypophysial "chromophobic zone" that fluctuated in size and cell number in reponse to sex hormone administration. His description indicates that this area corresponds to the ventral cyanophilic zone (meso-adenohypophysis) of the platyfish. It is conceivable that one might infer the presence of such a chromophobic zone even in the platyfish but only in Susa-fixed, azan-stained specimens. When it was ascertained that this response was not obtained with other methods of fixation (*e.g.,* formol-sublimate, chrome alum, etc.), we decided to eliminate the use of the Susa fixative as well as others containing acetic acid (see p. 219). The cyanophils of the ventral zone of the meso-adenohypophysis appear to be especially vulnerable to improper fixation. Vervoort (1957), also employing Susa-fixed, azan-stained guppy pituitaries, could not demonstrate acidophils in a region that corresponds to the acidophil-containing mid-dorsal region of the meso-adenohypophysis in *X. maculatus.* Another example of the interdependence of fixation and staining is the reaction of meta-adenohypophysial cyanophils to anilin blue following various fixatives (see p. 221).

Dempsey & Wislocki (1945) and Purves & Griesbach (1957), as well as others, have pointed out the fallacy of using the term "basophil" with trichrome staining because all these stains are acid stains and true basophilia cannot be indicated with their use. Vervoort (1957) went so far as to assert that it may be impossible to characterize any cells by specific staining reaction since this is dependent on such variables as previous fixation, pH of the stains, and duration of staining. In the present investigation, the term *acidophil* is applied to those cells that possess granules exhibiting an affinity for azocarmine and/or orange G and are PAS- and aldehyde fuchsin-negative. *Cyanophils* are cells containing cytoplasmic granules that stain with anilin blue and are positive for the PAS and aldehyde fuchsin reactions. *Chromophobes* are refractory or faintly staining cells.

There is one cell type, the agranular, generally spindle-shaped cell of the meta-adenohypophysis, that evades classification by the above tinctorial standards. From observations on its staining response (see p. 222), one cannot help but draw the analogy of the cell cytoplasm to a sponge that will take up any dye in solution presented to it. It is not likely that this represents an artifact, for this type of reaction was manifested with all of the fixatives and staining procedures used. This cell type may represent a degenerate or intermediate cell from the meta-adenohypophysis—and perhaps the meso-adenohypophysis as well. In various species of teleosts "acidophils" have been identified in the meta-adenohypophysis (Scruggs, 1939; Kerr, 1942, 1948), but no such cellular elements have been recognized in the meta-adenohypophysis of the platyfish.

B. The Pituitary Gland in Platyfish One to Eight Weeks Old

The thyroid gland of the embryonic guppy undergoes gradual increase in activity during the terminal stages of gestation (Stolk, 1951). A similar state of affairs is also indicated by the report of Tavolga (1949) in which he stated that the thyroid is developed and functional in the embryonic platyfish. Tavolga found no evidence of sexual dimorphism in the gonads nor any indication of somatic cells transforming into germ cells up to the time of birth. In the pituitary

gland of one-week-old platyfish, only the dorsal cyanophils of the meso-adenohypophysis are in evidence; no peripheral cyanophils are present. It is generally accepted that a cyanophilic cell type is responsible for the elaboration of TSH. Presumably, the cyanophils of one-week-old platyfish, which are structurally similar to the cyanophils of the adult dorsal meso-adenohypophysis, are related to the activity of the thyroid gland.

On the other hand, the cyanophils of the peripheral meso-adenohypophysis first appear in six-week-old fish as a few sparsely granulated cells dispersed among more numerous chromophobes. At eight weeks postpartum, a thin ventral layer (in sagittal section) composed of fully granulated cyanophils has developed. At six weeks postpartum, there is also a thickening and elongation of the anal fin in males, the beginning of the gonopodium. Experiments involving castration and sex hormone administration have demonstrated that this structure is formed under the influence of androgens (Pickford & Atz, 1957, pp. 86, 180). Coincident with the increase in number of fully granulated ventral meso-adenohypophysial cyanophils, at eight weeks postpartum male and female platyfish show signs of sexual maturity, that is, sperm and oocytes are present in the gonads. It is felt, therefore, that the cyanophils of the ventral meso-adenohypophysis, which are also strikingly affected by castration, are concerned with gonadal maturation and sexual maturity and thus involved in the production of gonadotrophin. The time of appearance of the two classes of cyanophils in the platyfish meso-adenohypophysis does not differ markedly from that indicated for the guppy. In the latter species, Sokol (1956) found the cyanophils of the ventral region appear several weeks later than those of the central meso-adenohypophysis.

Intermedin, which is implicated in the production of melanophores, is stored, if not elaborated, in the meta-adenohypophysis (Pickford & Atz, 1957, p. 44). The meta-adenohypophysis is a comparatively large glandular region in one-week-old platyfish. This observation may be related to the fact that pigmentation occurs early in the embryogenesis of this species (Tavolga, 1949). The expression of the spotted dorsal gene *(Sd)*, evident at birth as light pigmentation on the dorsal fin, becomes quite marked at six weeks of age. At this time, a noticeable degranulation of the purple cyanophils in the meta-adenohypophysis is evident. These observations suggest that these two events may be related.

There still remains the question of the significance of the large population of acidophils characteristic of pituitary glands in young platyfish. From the evidence to be presented, it does not seem unreasonable to assume that at least part of their function is involved in growth. During the first eight weeks of postpartum development, the average total length of the fish more than doubles. Present evidence indicates that a class of acidophils is concerned with the production of growth hormone (Barrnett, Siperstein & Josimovich, 1956), and there is no doubt that a growth hormone is present in pituitary glands of teleosts (Pickford & Atz, 1957, p. 91). In salmon parr and smolt, for example, Olivereau (1954) has demonstrated that there is an intense fuchsinophilia with Masson trichrome preceding periods of marked growth.

C. Aging Effects on the Pituitary Gland of Platyfish

The major problem in conducting aging studies is the acquisition of suitable material for investigation. As a result, literature dealing with aging effects on the endocrines is quite meager, exceptionally so for fishes. Interpretation of changes in pituitary morphology accompanying the onset of senility is difficult unless structural and functional changes in target organs and determination of circulating levels of hormones can be evaluated, which was not attempted in this study. Stating that a cell is "active" or "inactive," "granulating" or "degranulating," is often a questionable procedure unless the above parameters are taken into consideration.

In what seems to be the only report dealing with aging effects on the fish testis, Rasquin & Hafter (1951) called attention to the similarity of the changes they found in *Astyanax* to those described in other vertebrates. They described connective tissue infiltration and formation of "concretions" in the lobules and spermatic ducts. Of special interest is their finding of areas of active spermatogenesis even in the testes of a six-year-old fish. Generally, the reproductive capacity of live-bearing poeciliids decreases with age (Gerking, 1959). Baker-Cohen (1961) found that after the attainment of maturity there is a marked decline in thyroid activity in the platyfish. Both thyroid and testis are under the control of the pituitary, and the changes accompanying senility might therefore be reflected in the cyanophil population of that gland. In female platyfish, both the peripheral and central cyanophils of the meso-adenohypophysis exhibit distinct changes associated with increased age.

The report presented here for pituitaries from aging female platyfish shows many similarities (*e.g.*, increased chromophobia, decreased acidophilia, vacuolation of some cyanophilic elements) to the changes reported for the hamster

(Spagnoli & Charipper, 1955) and man (Kinsell, 1961). The paucity of related information essential to evaluate these morphological changes is well illustrated by Kinsell's conclusion that "no definite functional interpretation of histologic changes is possible at this time."

E. Pituitaries in Pregnant Platyfish

The marked enlargement of the meso-adenohypophysis in gravid platyfish is reflected in the increased size of the total pituitary gland. The dimensions reported by Vervoort (1957) for the hypophysis in the pregnant guppy, are comparatively smaller (200 × 100 micra for the guppy in contrast to 543.2 × 213.3 micra).

In the gravid platyfish, glandular increase is associated with hypertrophy, hyperplasia, and degranulation of the peripheral cyanophils and a marked increase in number, but not in size, of the red-orange acidophils of the dorsal meso-adenohypophysis. A series of projected drawings of serial sections by Baker-Cohen (1961) of the pituitary of an untreated gravid platyfish, also shows an enlarged glandular area, especially along the ventral surface. This enlarged zone can be attributed to the hypertrophy and hyperplasia of the peripheral cyanophils characteristic of gravid platyfish. Sokol (1961) reported an inverse relationship between the acidophils and ventral cyanophils of the meso-adenohypophysis of the guppy. In the gravid guppy, near the time of parturition and during the early days of a subsequent pregnancy, the ventral cyanophils are devoid of granules, and the meso-adenohypophysial acidophils exhibit maximum activity, that is, they are highly granular. If this is true in platyfish, it would seem that the majority of the animals in this study were in either the early or the late stages of pregnancy.

It appears probable that prolactin is synthesized by acidophils (Barrnett, Siperstein & Josimovich, 1956; Riddle, 1963). Friedgood & Dawson (1938, 1940) have shown that carminophils fluctuate in number during the reproduction cycle of rabbits and cats and that this is associated with pregnancy and lactation. In mammals, prolactin or luteotrophin (LTH) is generally considered to be responsible for the initiation of progesterone secretion by the corpus luteum. In the platyfish, the appearance of increased numbers of acidophils during pregnancy is somewhat of an enigma in light of the conclusion of Pickford & Atz (1957, p. 221) that "there is no indisputable evidence for the endocrine nature of the so-called corpus luteum of the teleost." Nevertheless, Egami & Ishii (1962) have demonstrated that prolactin is effective in maintaining gestation in two genera of fish, *Gambusia* and *Ditrema*. Perhaps prolactin works synergistically in the regulation of gonadotrophins and sex hormones in fish as Pickford (1959) suggested. At this level of the phylogenetic scale, prolactin may also have different physiological roles, as for example in pigment formation (Pickford & Kosto, 1957), parental behavior (Riddle, 1963), and in mucus production in the skin of post-spawning, parental *Symphysodon discus* (Egami & Ishii, 1962). Of course there is also the possibility that no relationship exists between the acidophil hyperplasia and prolactin elaboration and secretion in the platyfish.

F. Pituitaries of Thyroid Tumorous Platyfish

In response to an iodine deficient environment (*i.e.*, distilled water), platyfish develop a goitrous condition. This "tumorous state" can be mitigated simply by the addition of iodine to the diet of these fish (Baker, 1958b). The thyroid hyperplasia is undoubtedly brought about by increased thyrotrophin (TSH) release in response to a deficiency of thyroxine in the blood stream. This manifestation is comparable to that achieved when thiouracil is administered (Turner, 1960; Goldsmith *et al.*, 1944).

The pituitary cytology of platyfish with thyroid tumors presumably reflects this marked release of TSH from the pituitary. Only the cyanophils in the mid-region of the meso-adenohypophysis exhibit a marked degranulation, loss of PAS- and aldehyde fuchsin-positive material, and a dramatic increase in cell number and size, including an almost threefold increase in cellular dimensions. No vacuolation comparable to what is found in the thyroidectomy cells of the rat has ever been observed. On the other hand, the peripheral cyanophils, as a result of a decrease in their volume, appear to be much denser. The appearance of the peripheral cyanophil is similar to the change in the gonadotrophs that accompanies thyrotroph degranulation in thiourea-treated and ACTH- and cortisone-treated *Astyanax* (Atz, 1953).

Our observations are in agreement with the description presented by Öztan (1961). Degranulation of specific cyanophils in response to thiourea treatment has also been recorded for *Brachydanio rerio* (Scott, 1953), *Phoxinus phoxinus* (Barrington & Matty, 1955), *Dentex dentex* (Leloup & Olivereau, 1950) and *Poecilia reticulata* (Sokol, 1955). Radioiodine (I^{131}) administered to *Anguilla anguilla* also evoked a characteristic hyperplasia, hypertrophy and deganulation of cyanophils (Olivereau, 1963). Honma & Murakawa (1955) reported that in thiourea-treated salmon larvae, an enlargement of the cells in the transitional lobe occurs, but they did not specify the cell types affected. The significance of the loss of aldehyde fuchsin- and

PAS-positive granules, as seen in the platyfish, has been discussed for the rat. A rising level of TSH in the blood is inversely related to the loss of aldehyde fuchsin-positive (Del Conte & Stux, 1955) or PAS-positive (Purves & Griesbach, 1951a) material. On the other hand, there are reports on related phenomena that are difficult to reconcile with the present investigation of thyroid-tumor bearing platyfish and the large body of supporting information that is available. For example, Rasquin (1949) found no change in basophil counts of thiourea-treated *Astyanax,* Stolk (1956a, b, c) reported no cytological changes in three genera of thyroid tumorous fish, although he does note an increase in glandular area, and Baker-Cohen (1961) found no cellular increase in the pituitaries of "severely hypothyroid or completely athyroid fish" (radioiodine treated young fish). In the last instance, Baker-Cohen suggested that this may be an example of an exhausted pituitary.

In her report, Baker-Cohen (1961) described a "prominent overgrowth of pale intermediate basophiles" in radioiodine-treated adult platyfish. In addition, she reported that in several fish with thyroid hypertrophy, the pituitary structure had changed; there was "a marked overgrowth of the paler intermediate basophiles, so that these overlapped the darker anterior basophiles ventrally, causing the appearance of a sharp line of demarcation in the anterior region and a distortion of the usually round cross-section of the hypophysis at that point." Although evaluation of this description is difficult because of the terminology used for location and cell types, the cellular "overgrowth" Baker-Cohen described might be the result of the same hypertrophy and hyperplasia of the central meso-adenohypophysial cyanophils found in goitrous fish of the present study.

G. Effects of Castration on the Pituitary of Male Platyfish

Information on the effects of castration on teleost pituitaries is conspicuously absent. The only report involving surgical castration appears to be Sokol's (1955) study of ovariectomized guppies, but she fails to give any cytological detail. Atz (1953) has presented a cytological description of the pituitary in physiological castrates. *i.e., Astyanax* that were reared in the dark.

In surgically castrated male platyfish, the cyanophils of the peripheral meso-adenohypophysis contain vacuoles, exhibit degranulation, are hypertrophied, and have increased in number. Typical "castration cells", although characteristically present, are not numerous. Severinghaus (1939) indicated that marked hyperplasia is a more prominent feature of the pituitaries of castrate mammals than the presence of signet-ring cells. This also holds for the pituitaries of surgically castrated male platyfish with their paucity of "castrate cells" and prominent cyanophil hyperplasia and hypertrophy. The description of the castration cell in *Astyanax* (Atz, 1953) and the rat (Purves & Griesbach, 1951a) does not differ essentially from the one described in castrated male platyfish.

In the platyfish, cyanophils that respond strikingly to castration are confined to the peripheral area of the meso-adenohypophysis as also reported for the castrate female guppy (Sokol, 1955). In *Astyanax,* this cell type is found in the central area in addition to the peripheral location (Atz, 1953). In reviews of the literature on pituitary cytology in teleosts, Olivereau (1962b, 1963) indicated that invariably the cells that are affected by reproductive cycles and functional variations in the gonads are located in a region that corresponds to the meso-adenohypophysis. Öztan (1963) reported that in sterile hybrids between platyfish and swordtails, "peculiar adenohypophyseal basophils" are degranulated, smaller, and fewer in number, but unfortunately she did not give the location of these cells. In an earlier report, however, Öztan (1961) cited unpublished data and suggested that "type 3" cells (which correspond to the peripheral cyanophils of the meso-adenohypophysis, p. 221) may be involved in gonadotrophic function.

The cyanophils of the central meso-adenohypophysis that change vividly in platyfish with thyroid neoplasms also appear to be altered in castrate males, *i.e.,* they increase somewhat in cell and nuclear dimensions and exhibit some degranulation. It has been demonstrated that the thyroid gland generally plays an important role in gonadal development in many animals and that interference with thyroid function may be reflected in the delay of sexual maturity (Barrington & Matty, 1952; Baker-Cohen, 1961) or the development of secondary sex characters (Goldsmith *et al.,* 1944; Nigrelli, Goldsmith & Charipper, 1946). Perhaps the cytological changes of the central cyanophils, which the present study has shown to be responsive to iodine deficiencies, may be a manifestation of a thyroid-gonad syndrome.

The inability to identify cells undergoing mitosis is puzzling in pituitary glands that exhibit marked hyperplasia, *e.g.,* in castrated and goitrous platyfish. Perhaps the proliferation of cellular elements exhibits a periodicity such as that frequently encountered in proliferating plant and animal tissues, *e.g.,* regenerating rat liver and onion root meristematic tissue, and the time chosen for fixation may not have coincided with

cell division. This would imply that all investigators have killed and fixed their specimens at a time of minimal cell division because mitotic figures have been so infrequently reported in the pituitary gland. Van Mullem (1958) speculated on the possibility that pituitary cells may divide amitotically in addition to a normal mitotic process. His hypothesis, however, is based solely on the frequency of variably shaped nuclei (*e.g.*, bean-shaped, indented) that he encountered.

H. Pituitaries in Fish With Melanotic Tumors

Mac Intyre & Baker-Cohen (1961) described the pituitary of a spike-tailed platyfish *(Xiphophorus variatus xiphidium)* that exhibited both melanoma and thyroid tumor. Although the hypophysis in this fish "was not sectioned or stained in a manner suitable for the demonstration of cell types," these investigators discovered abnormalities described as follows:

> "In the anterior part of the gland, the vertical cross-section was much elongated; the elongation was made up of a homogeneous mass of light staining basophils. Eosinophils were not delineated by the staining methods employed. Normally, at that cross-sectional level, the pituitary is round and chiefly composed of darkly staining basophils; the paler cells appear in small numbers along the ventral border and increase somewhat in the posterior direction, as the neural portion of the hypophysis appears. In the tumorous fish, the anterior basophilic overgrowth also continued along the entire length of the pituitary, making the entire organ misshapen."

Mac Intyre & Baker-Cohen stated that this overgrowth of "paler basophilic elements" was also seen in *X. maculatus* with goitrous thyroids or with regenerating thyroid tissue after radioiodine administration. Although the present work did not include a specimen with both pathological conditions, it is difficult to apply this description to either our melanomatous fish or fish with thyroid tumors. In the present study, thyroid tumorous fish were found to possess pituitaries with hyperplasia and hypertrophy of the central meso-adenohypophysial cyanophils, while in pituitaries from melanomatous fish, the acidophil population was most affected. The inability of Mac Intyre & Baker-Cohen to see a change in the acidophil population can be attributed to the fact that they were unable to demonstrate acidophils. In another spike-tailed platyfish with extreme melanosis, but no thyroidal neoplasm, Mac Intyre & Baker-Cohen (1961) failed to note any structural differences in the pituitary. This fish had been fixed by "slow formalin fixation."

Hypertrophy of the pro-adenohypophysial acidophils and marked hyperplasia of the meso-adenohypophysial acidophils are the most striking features of pituitary glands in melanoma-bearing platyfish. Less consistent is the hypertrophy (statistically insignificant) of the cyanophils of the meta-adenohypophysis. Levenstein's (1939) differential counts revealed that a greater number of acidophils are present in the transitional lobe (meso-adenohypophysis) of the black moor goldfish than in the common goldfish. He suggested that the somatic differences between these two varieties (*i.e.*, abnormal growth pattern, telescopic eyes and black pigmentation) may be reflected in the difference in pituitary chromophil cell counts. The association of increased acidophilia of the "transitional lobe" with black-pigmented goldfish is interesting in the light of the enhanced acidophilia found in the hypophyses of platyfish with melanoma.

Chavin (1956) indicated changes in the pituitary cytology of the goldfish after various hormonal treatments designed to analyze the role of these substances in melanogenesis, but he did not discuss the significance of the cytological changes. He found that ACTH stimulates melanogenesis in both hypophysectomized and intact goldfish. The administration of ACTH alone, or in conjunction with intermedin, causes the acidophils of the transitional lobe (meso-adenohypophysis) to enlarge, become densely granulated, and stain deep red (with Masson stain); there is no variation in the pro-, meta-, or neurohypophysis (our terminology) with this treatment. Chavin (1959) found that in xanthic goldfish, surgical removal of the pars tuberalis (pro-adenohypophysis) and pars distalis (meso-adenohypophysis) inhibits melanogenesis. In contrast, extirpation of the pars intermedia (meta-adenohypophysis) has no effect.

Pickford (1956) and Pickford & Kosto (1957), however, have demonstrated that prolactin is the pituitary hormone necessary for melanogenesis in *Fundulus heteroclitus.* They found that sheep prolactin alone will increase melanin in pre-existing melanophores; when this hormone is administered in conjunction with intermedin, both an increase in melanin formation and the appearance of new melanophores occurs. In contrast, no melanogenesis follows the administration of ACTH. A later report, with *in vivo* observations and *in vitro* biochemical assays, confirmed the latter observation and indicated that the action of ACTH resembles intermedin (Kosto, Pickford & Foster, 1959). If, as claimed by these authors, prolactin is essential for melanogenesis in *Fundulus,* our observation that the pituitaries of melanomatous and gravid

platyfish exhibit a hyperplasia of the meso-adenohypophysial acidophils, may indicate that these acidophils are, (1) involved in both pregnancy and melanogenesis, and (2) that the secretion of these cells is prolactin.

Because a species difference in the hormonal control of melanogenesis could very well be possible, an investigation of this process in platyfish would undoubtedly yield useful comparative information.

The foregoing might suggest that there are two physiologically distinct classes of acidophils in the meso-adenohypophysis, *viz.*, those concerned with both gestation and melanization and others associated with growth hormone. However, morphologically only one type of acidophil was detected in the meso-adenohypophysis. Perhaps this differentiation awaits a more sophisticated probe. It is also conceivable that one cell type may elaborate more than one active substance.

The possible existence of a melanophore-concentrating hormone originating in the pro-adenohypophysis (Pickford & Atz, 1957; p. 35-36) may partially explain the hypertrophy of pro-adenohypophysial acidophils in melanoma-bearing platyfish. It is also possible that another hormone from the pro-adenohypophysis may play an as yet unelucidated role in the melanotic and melanomatous hybrids.

I. Distribution of Thyrotrophs and Gonadotrophs in the Platyfish Pituitary and an Evaluation of the Periodic Acid-Schiff and Aldehyde Fuchsin Tests

From an analysis of PAS- and aldehyde fuchsin-stained specimens the following generalizations can be made:

(1) The two classes of meso-adenohypophysial cyanophils cannot be distinguished by their response to these techniques; thus gonadotrophs and thyrotrophs cannot be demarcated. With such differential methods, Purves & Griesbach (1951a, b, c) and Halmi (1952) were able to delineate two classes of cyanophils in mammalian pituitaries and Barrington & Matty (1955) accomplished this in the minnow. Atz (1953) and Sokol (1955), however, could not separate two classes of cyanophils on the basis of differential staining responses.

(2) The intensity of the reaction with these techniques corresponds to the degree of cyanophilia.

(3) The application of aldehyde fuchsin is an excellent means of demonstrating neurosecretory granules and Herring bodies in the neurohypophysis.

The identification of thyrotrophs in the central part of the meso-adenohypohysis and gonadotrophs in the peripheral zone has been possible on the basis of the following indirect evidence presented in this report:

(a) Marked hypertrophy and degranulation of only the central cyanophils occur in response to a deficient iodine environment.

(b) Conspicuous hypertrophy, hyperplasia, and vacuolation of the peripheral cyanophils distinguish pituitaries of castrate males.

(c) Striking changes take place in the peripheral cyanophils of gravid platyfish.

(d) The presence of dorsal cyanophils early in the postpartum development of *X. maculatus* at the time when a functional thyroid is already present. The appearance of a peripheral cyanophilic layer later in postpartum development synchronous with gonadal maturation.

Summary

1. The pituitary gland of *Xiphophorus maculatus* is composed of four regions: pro-adenohypophysis, meso-adenohypophysis, meta-adenohypophysis and neurohypophysis.

2. The pro-adenohypophysis occupies the most anterior portion of the gland and is populated by carminophilic acidophils, which predominate, and chromophobes. A peninsula of chromophobic cells and a connective tissue septum form the posterior boundary of the pro-adenohypophysis.

3. Two regions in the meso-adenohypopohysis are distinguishable: a central portion composed of orange acidophils (with Heidenhain's azan) and round cyanophils that are grouped in islets formed by penetrating strands of neurohypophysial tissue, and a peripheral zone of cyanophils that vary in shape and size. Small numbers of chromophobes are dispersed in this region.

4. The meta-adenohypophysis, which comprises the posterior part of the gland, is made up of round or oval cyanophils and a second cell type that is generally spindle-shaped and agranular.

5. The neurohypophysis is characterized by a highly branched network of fibroid material, large nuclei, neurosecretory granules and Herring bodies. Its ramifications penetrate all the glandular portions to varying degrees. Ependyma cells border on the infundibular cavity and hypophysial recess.

6. No distinction can be made between the two classes of meso-adenohypophysial cyanophils based on a differential response to PAS and aldehyde fuchsin. The intensity of the reaction with these techniques corresponds to the degree of cyanophilia.

7. In one-week-old fish, the neurohypophysis and adenohypophysis occupy about equal areas. Except for the cyanophils of the peripheral meso-adenohypophysis, all cell types that can be identified in the pituitaries of mature specimens are present in one-week-old fish. Cyanophils of the peripheral meso-adenohypophysis are not evident until six weeks postpartum; by eight weeks they have increased in number and contain more granules. The significance of the differential appearance of the two classes of cyanophils and the possible role of the various cell types in the early development of platyfish is discussed.

8. In the pituitary of aging female platyfish one finds: an increased chromophobia, hypertrophy and degranulation of the peripheral cyanophils, a decrease in cell and nuclear size of the central cyanophils and an apparent increase of neurohypophysial tissue. There also appears to be a change in hypophysial shape with senility.

9. Pituitaries of fish with heterotopic thyroid tumors exhibit a pronounced protuberance of the meso-adenohypophysis and degranulation, hypertrophy and hyperplasia of the central cyanophils. The cyanophils of the peripheral and protuberant areas are smaller, hyperchromic and dispersed.

10. Hyperplasia, hypertrophy and prominent vacuolation of the peripheral cyanophils characterize the pituitaries of surgically castrated males. A description of "castration cells" as they appear in platyfish is provided. Central cyanophils are irregularly shaped and slightly enlarged. An increase in the dimensions of the meso-adenohypophysis is reflected in an increase of the total gland volume.

11. The hypophysis of gravid platyfish can be identified by a prominent increase in the width of the peripheral layer of cyanophils and hyperplasia of the central meso-adenohypophysial acidophils. Peripheral cyanophils have increased in number and size. Their cytoplasm is hyaline in appearance and contains many spherical droplets and clear vacuoles.

12. Hyperplasia of the meso-adenohypophysial acidophils and hypertrophy of the pro-adenohypophysial acidophils distinguish the pituitary of melanomatous fish. Cellular elements of the meta-adenohypophysis are insignificantly enlarged. The significance of the hyperplasia of the meso-adenohypophysial acidophils in both melanomatous and gravid platyfish is discussed in the light of recent theories of hormonal control of melanogenesis.

13. The evidence is discussed that permits identification of thyrotrophs in the central meso-adenohypophysis and gonadotrophs in the peripheral meso-adenohypophysis of the platyfish pituitary.

14. Data are given for glandular and cellular dimensions and differential cell counts reported for most classes of pituitaries investigated.

Bibliography

Atz, Ethel Hafter

1953. Experimental differentiation of basophil cell types in the transitional lobe of the pituitary of a teleost fish, *Astyanax mexicanus*. Bull. Bingham Oceanogr. Coll., 14: 94-116.

Baker, K. F.

1958a. Heterotopic thyroid tissues in fishes. I. The origin and development of heterotopic thyroid tissue in platyfish. J. Morph., 103: 91-134.

1958b. Heterotopic thyroid tissues in fishes. II. The effect of iodine and thiourea upon the development of heterotopic thyroid tissue in platyfish. J. Exp. Zool., 138: 329-354.

Baker-Cohen, K. France

1961. The role of the thyroid in the development of the platyfish. Zoologica, 46: 181-222.

Baker- K. F., O. Berg, A. Gorbman, R. F. Nigrelli & M. Gordon

1955 Functional thyroid tumors in the kidneys of platyfish. Can. Res., 15: 118-123.

Barrington, E. J. W., & A. J. Matty

1952. Influence of thiourea on reproduction in the minnow. Nature, Lond., 170: 105-106.

1955. The identification of thyrotrophin-secreting cells in the pituitary gland of the minnow *(Phoxinus phoxinus)*. Quart. J. Micr. Sci., 96: 193-201.

Barrnett, R. J., E. Siperstein & J. B. Josimovich

1956. The localization of simple protein hormones in the adenohypophysis demonstrated by combined use of differential protein solubilities, histochemical staining and bioassay. Anat. Rec., 124: 388.

Bell, W. Randal

1938. Morphology of the hypophysis of the common goldfish (*Carassius auratus* L.). Zoologica, 23: 219-234.

Chavin, Walter

1956. Pituitary-adrenal control of melanization in xanthic goldfish, *Carassius auratus* L. J. Exp. Zool., 133: 1-46.

1959. "Pituitary hormones in melanogenesis." *In:* Pigment Cell Biology. Academic Press, Inc., N.Y., pp. 63-83.

Dawson A. B., & H. B. Friedgood

1938. Differentiation of two classes of acidophils in the anterior pituitary of the female rabbit and cat. Stain Tech., 13: 17-21.

Del Conte, E. & M. Stux

1955. Effect of thyroidectomy, thiourea and iodine on the circulating thyrotrophin and pituitary thyrotroph cells in rats. Acta Endocrinol., 20: 246-256.

Dempsey, E. W., & G. B. Wislocki

1945. Histochemical reactions associated with basophilia and acidophilia in the placenta and pituitary gland. Amer. J. Anat., 76: 277-302.

Egami, Nobuo & Susumu Ishii

1962. Hypophyseal control of reproductive functions in teleost fishes. Gen. & Comp. Endocrinol., Supplement 1: 248-253.

Elftman, H.

1957. A chrome-alum fixative for the pituitary. Stain Tech., 32: 25-28.

1959. Aldehyde-fuchsin for pituitary cytochemistry. J. Histochem. Cytochem., 7: 98-100.

Friedgood, H. B., & A. B. Dawson

1938. Cytologic evidence of the gonadotropic activity of the rabbit's anterior hypophysis. Endocrinol., 22: 674-686.

1940. Physiological significance and morphology of the carmine cell in the cat's anterior pituitary. Endocrinol., 26: 1022-1031.

Gerking, Shelby D.

1959. "Physiological changes accompanying ageing in fishes." *In:* G. E. W. Wolstenholme & M. O'Connor, eds., The Lifespan of Animals, Ciba Foundation Colloquia on Ageing. Little, Brown & Co., Vol. 5, pp. 181-211.

Geske, Gerhard

1956. Untersuchungen über den einfluss von p-oxy-propiophenon, methyl-testosteron und äthinyl-oestradiol auf die innersekretorischen organe von *Lebistes reticulatus* (Peters). Roux' Archiv. für Entwicklungsmechanik Der Organismen, 148: 263-310.

Goldsmith, E. D., R. F. Nigrelli, A. S. Gordon, H. A. Charipper & M. Gordon

1944. Effect of thiourea upon fish development. Endocrinol., 35: 132-134.

Gomori, G.

1950. Aldehyde-fuchsin: A new stain for elastic tissue. Amer. J. Clin. Path., 20: 665-666.

Gordon, M.

1950. "Fishes as laboratory animals." *In:* Care and Breeding of Laboratory Animals, E. J. Farris Ed. John Wiley & Sons Inc., N.Y., Chap. 14, pp. 345-449.

1951. Genetic and correlated studies of normal and atypical pigment cell growth. Growth, Symposium, 10: 153-219.

Halmi, Nicholas S.

1950. Two types of basophils in the anterior pituitary of the rat and their respective cytophysiological significance. Endocrinol., 47: 289-299.

1952. Differentation of two types of basophils in the adenohypophysis of rat and mouse. Stain Tech., 27: 61-64.

Hildebrand, J. E., E. G. Rennels, & J. C. Finerty

1957. Gonadotrophic cells of the rat hypophysis and their relation to hormone production. Zeitschrift für Zellforschung, 46: 400-411.

Honma, Y. & S. Murakawa

1955. "Effects of thyroxine and thiourea on the development of chum salmon larvae." Jap. J. Ichthyol., 4: 83-93. *Cited In:* Pickford, Grace E., & James W. Atz, 1957, The Physiology of the Pituitary Gland of Fishes, New York Zoological Soc., New York, p. 157.

Kerr, T.

1942. A comparative study of some teleost pituitaries. Proc. Zoological Soc., Ser. A., 112: 37-56.

1948. The pituitary in normal and parasitized roach (*Leuciscus rutilus* Flem.) Quart. J. Micr. Sci., 89: 129-138.

Kinsell, Laurence W.

1961. Physiologic ageing and radiologic life-shortening. Fed. Proceed., 20: 14-21. Suppl. #8, Part II.

Kosto, Bernard, Grace E. Pickford & Morris Foster

1959. Further studies of the hormonal induction of melanogenesis in the killifish, *Fundulus heteroclitus*. Endocrinol., 65: 869-881.

Krajian, Aram A.

1940. Histological Technic. C. V. Mosby Co., St. Louis, Missouri.

Leloup J., & M. Olivereau

1950. Production d'exophthalmie par la thiourée chez un téléostéen marin: *Dentex vulgaris* Cuv. Compt. Rend. Soc. Biol., 144: 772-774.

Levenstein, Irving

1939. The cytology of the pituitary gland of two varieties of goldfish (*Carassius auratus* L.), with some reference to variable factors in the gland which may possibly be related to the different morphological types. Zoologica, 24: 47-60.

Lillie, R. D.

1954. Histopathologic Technic and Practical Histochemistry. The Blakiston Co., Inc., N.Y. and Toronto.

Mac Intyre, Pamela A.

1960. Tumors of the thyroid gland in teleost fishes. Zoologica, 45: 161-170.

Mac Intyre, Pamela A., & K. France Baker-Cohen

1961. Melanoma, renal thyroid and reticulo-endothelial hyperplasia in a non-hybrid platyfish. Zoologica, 46: 125-132.

Mathews, Samuel A.

1936. The pituitary gland of *Fundulus*. Anat. Rec., 65: 357-367.

McManus, J. F. A., & Robert W. Mowry

1960. Staining Methods Histologic and Histochemical. Paul B. Hoeber, Inc., N.Y.

Nigrelli, R. F., E. D. Goldsmith & H. A. Charipper

1946. Effect of mammalian thyroid powder on growth and maturation of thiourea treated fishes. Anat. Rec., 94: 523.

Olivereau, Madeline

1954. Hypophyse, et glande thyröide chez les poissons. Etude histophysiologique de quelques corrélations endocriennes en particulier chez *Salmo salar* L. Année Biol., 30: 63-80.

1962a. Cytologie de l'hypophyse du Cyprin (*Carassius auratus* L.). C. R. Acad. Sci., 255: 2007-2009.

1962b. Cytologie adénohypophysaire chez les Agnathes, les Poissons et les Amphibiens. Biol. Méd., 51: 172-179.

1963. Effets de la radiothyroïdectomie sur l'hypophyse de l'Anguille. Discussion sur la pars distalis des Téléostéens. Gen. & Comp. Endocrinol., 3: 312-332.

Ortman, R.

1961. A note on the cytology of the pituitary of *Gadus morhua*. Amer. Zool., 1: 465-466.

Öztan, Nezihe

1961. Adenohypophyseal basophiles and I^{131} utilization in thyroidal tumor bearing platyfish *(Xiphophorus maculatus)*. Rev. Fac. Sci. Univ. Istanbul. B26: 21-35.

1963. The hypothalamic neurosecretory system of a poeciliid fish, *Platypoecilus maculatus* and its sterile hybrid backcross with *Xiphophorus helleri*. Gen. & Comp. Endocrinol., 3: 1-14.

Pickford, Grace E.

1956. Melanogenesis in *Fundulus heteroclitus*. Anat. Rec., 125: 603-604.

1959. "The nature and physiology of the pituitary hormones of Fishes." *In:* Comparative Endocrinology. A. Gorbman, Ed. John Wiley & Sons Inc., N.Y., pp. 404-420.

Pickford, Grace E., & James W. Atz

1957. The Physiology of the Pituitary Gland of Fishes. New York Zoological Society, New York.

Pickford, Grace, & Bernard Kosto

1957. Hormonal induction of melanogensis in hypophysectomized killifish *(Fundulus heteroclitus)*. Endocrinol., 61: 177-196.

Potts, Hugh E.

1942. The anatomy and morphology of the hypophysis of several species of ovo-viviparous poeciliids. Zoologica, 27: 85-95.

Purves, H. D., & W. E. Griesbach

1951a. The site of thyrotrophin and gonadotrophin production in the rat pituitary studied by McManus-Hotchkiss staining for glycoprotein. Endocrinol., 49: 244-264.

1951b. Specific staining of thyrotrophic cells of the rat pituitary by the Gomori stain. Endocrinol., 49: 427-428.

1951c. The significance of the Gomori staining of the basophils of the rat pituitary. Endocrinol., 49: 652-662.

1957. A study on the cytology of the adenohypophysis of the dog. J. Endocrinol., 14: 361-370.

Rasquin, Priscilla

1949. The influence of light and darkness on thyroid and pituitary activity of the characin *Astyanax mexicanus* and its cave derivatives. Bull. Amer. Mus. Nat. Hist., 93: 497-532.

Rasquin, Priscilla, & Ethel Hafter

1951. Age changes in the testis of the teleost, *Astyanax mexicanus*. J. Morph., 89: 397-408.

Riddle, Oscar

1963. Prolactin in vertebrate function and organization. J. Nat. Can. Institute., 31: 1039-1110.

Scott, J. L.

1953. The effects of thiourea treatment upon the thyroid, pituitary and gonads of the zebra fish, *Brachydanio rerio*. Zoologica, 38: 53-62.

Scruggs, W. M.

1939. The epithelial components of the teleost pituitary gland as identified by a standardized method of selective staining. J. Morph., 65: 187-214.

Severinghaus, Aura E.

1939. "Anterior hypophysial cytology in relation to the reproductive hormones." *In:* Sex and Internal Secretions. The Williams and Wilkins Co., Baltimore. Chap. 19.

SOKOL, H. W.

1955. Experimental demonstration of thyrotrophic and gonadotropic activity in the adenohypophysis of the guppy. Anat. Rec., 122: 451.

1956. Cytophysiological studies on the teleost hypophysis. Doctorate thesis, Radcliffe College, Cambridge, Mass., *Cited In:* Sokol, Hilda Weyl. 1961. Cytological changes in the teleost pituitary gland associated with the reproductive cycle. J. Morph., 109: 219-236.

1961. Cytological changes in the teleost pituitary gland associated with the reproductive cycle. J. Morph., 109: 219-236.

SPAGNOLI, H. H., & H. A. CHARIPPER

1955. The effects of ageing on the histology and cytology of the pituitary gland of the golden hamster *(Cricetus auratus),* with brief reference to simultaneous changes in the thyroid and testis. Anat. Rec., 121: 117-139.

STOLK, A.

1951. Activity of the embryonic thyroid gland in the viviparous cyprinodont *Lebistes reticulatus* (Peters). Proc. Kon. Ned. Akad. v. Wetensch., Amsterdam. 54: 579-584.

1956a. Changes in the pituitary gland of the cyprinid *Tanichthys albonubes* Lin. with thyroidal tumor. Proc. Kon. Ned. Akad. v. Wetensch., Amsterdam. C59: 38-49.

1956b. Changes in the pituitary gland of the cichlid *Cichlasoma biocellatum* (Regan) with thyroidal tumor. Proc. Kon. Ned. Akad. v. Wetensch., Amsterdam. C59: 494-505.

1956c. Tumours of fishes. VIII. Thyroidal tumour in the cyprinid *Tanichthys albonubes* (Lin). Kon. Ned. Akad. v. Wetensch., Amsterdam. C59: 50-60.

TAVOLGA, W. N.

1949. Embryonic development of the platyfish *(Platypoecilus),* the swordtail *(Xiphophorus),* and their hybrids. Bull. Amer. Mus. Nat. Hist., 94: 161-229.

TURNER, C. D.

1960. "The pituitary gland." *In:* General Endocrinology. W. B. Saunders Co., Phila. and London. Chap. 2, pp. 43-106.

VAN MULLEN, P. J.

1958. A histo- and cytological study on the pituitary of the stickleback *Gasterosteus aculeatus* L. forma *trachura* Cuv. partially based on a new fixation procedure after freeze drying. Arch. Neerlandaises de Zool., 13: 147-195.

VERVOORT, W.

1957. Note on the pituitary cytology of *Lebistes reticulatus* (Peters). Kon. Ned. Akad. v. Wetensch., Amsterdam, Proceedings, C60: 486-509.

EXPLANATION OF THE PLATES

Plate I

Fig. 1. Sagittal section of a pituitary from a sexually mature female. Dark area at the right is the pro-adenohypophysis with its characteristic abundance of carminophilic acidophils. Dark gray area at the extreme left is the meta-adenohypophysis. Between these two regions is the meso-adenohypophysis. The neurohypophysis is in the mid-dorsal position. Heidenhain's azan, formol-sublimate. 190×.

Fig. 2. High power view of carminophilic acidophils and adjacent cells (gray) of the wedge area in the pro-adenohypophysis. Light area at the extreme left is a portion of the neurohypophysis. 1025×.

Fig. 3. High power view of the central meso-adenohypophysis. Note islets of cells formed by pervading neurohypophysial tissue. 1025×.

Fig. 4. The cell types of the meta-adenohypophysis at high magnification. Note adjacent neurohypophysial tissue at the right of the picture. 1240×.

Plate II

Fig. 1. Sagittal section of a pituitary from a one-week-old platyfish. Anterior end is at the right. Chrome alum fixed, Heidenhain's azan stained. 460×.

Fig. 2. Pituitary of an eight-week-old fish; sagittal section. Compare with fig. 1. Acidophils are black; cyanophils are gray. In this photograph the anterior end is at the left. Arrow points to ventral cyanophil layer that is absent in one-week-old glands. 300×.

Fig. 3. High power view (sagittal) of the meso-adenohypophysis of the gland represented in fig. 1. Acidophils are black; cyanophils are lighter. Arrows in figs. 1 & 3 point to similar areas of the meso-adenohypophysis. 1240×.

Fig. 4. Higher magnification of the meso-adenohypophysis of gland depicted in fig. 2. Here cyanophils are black and acidophils are lighter. 1240×.

Plate III

Fig. 1. Aldehyde fuchsin response (black) in a gland of a sexually mature platyfish. Dark area towards the right of the gland is neurosecretory material in the neurohypophysis. Formol-sublimate. 170×.

Fig. 2. Distribution of PAS-positive material (black) in a sagittal section of a pituitary gland from a sexually mature fish. Compare with adjacent section represented in fig. 1. Formol-sublimate. 170×.

Fig. 3. Pituitary from a castrated male platyfish, in sagittal section. Note marked increase in ventral meso-adenohypophysial cyanophil layer (lighter lower area in mid-region of the gland). Helly fixed, azan stained. 160×.

Fig. 4. High power view of ventral cyanophil cell layer of a pituitary from a castrated male platyfish. Note "castration cells." 1240×.

Plate IV

Fig. 1. Sagittal section of a pituitary from a 28-month-old female platyfish. Note large chromophobic area (gray) in pro-adenohypophysis (left side). Heidenhain's azan following Helly's fixative. 230×.

Fig. 2. Mid-sagittal section through a pituitary from a fish with a heterotopic thyroid tumor. Note protuberance of meso-adenohypophysis (central portion). Dark area at extreme left is pro-adenohypophysis. 170×.

Fig. 3. High power of the mid-region of gland in fig. 2. Note large cells with loss of granules in central area and smaller, darker, and separated cells at periphery (bottom of picture). Chrome alum fixed, azan stained. 580×.

Fig. 4. Similar region as fig. 3 from another thyroid tumor-bearing platyfish. This section, however, was stained with aldehyde fuchsin. 460×.

Plate V

Fig. 1. Sagittal section of a hypophysis from a gravid fish. Note increased ventral meso-adenohypophysial cyanophil cell layer (lower mid-region). Note, too, many dark cells (acidophils) dorsal to this cyanophil layer. 170×.

Fig. 2. Higher magnification of gland from a gravid fish. Here hyperplasia of meso-adenohypophysial acidophils (black) and increased ventral cyanophil layer (light) is quite evident. 510×.

Fig. 3. Mid-sagittal section of a non-melanotic platyfish-swordtail hybrid pituitary. 230×.

Fig. 4. Pituitary of hybrid fish with a melanoma. Note especially the marked acidophil hyperplasia in the central (meso-adenohypophysis) region and hypertrophied acidophils and their nuclei of the pro-adenohypophysis (right side). Compare with fig. 3. 270×.